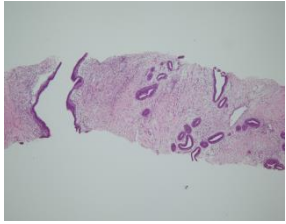


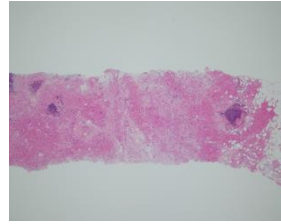
症例1



メモ

- a.線維腺腫
- b.葉状腫瘍
- c.非浸潤性乳管癌
- d.粘液癌
- e.管状癌

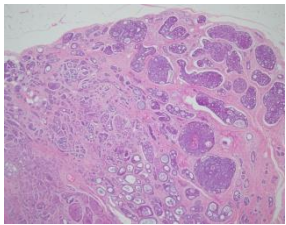
症例2



メモ

- a.顆粒細胞腫
- b.乳腺炎
- c.浸潤性乳管癌 硬性型
- d.浸潤性小葉癌
- e.アポクリン癌

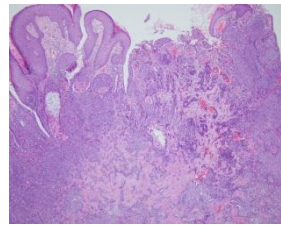
症例3



メモ

- a.線維腺腫
- b.非浸潤性乳管癌
- c.篩状癌
- d.粘液癌
- e.腺様嚢胞癌

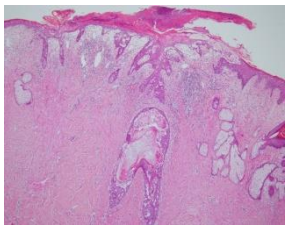
症例4



メモ

- a.乳頭部腺腫
- b.乳腺症
- c.非浸潤性乳管癌
- d.扁平上皮癌
- e. Paget病

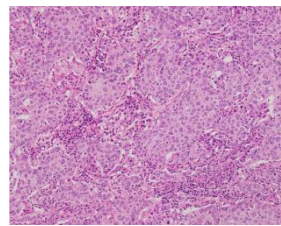
症例5



メモ

- a.乳頭部腺腫
- b.乳腺症
- c.扁平上皮癌
- d. Paget病
- e.悪性黒色腫

症例6



メモ

- a.腫瘍組織浸潤リンパ球 (tumor-infiltrating lymphocytes; TIL) あり
- b. TILなし