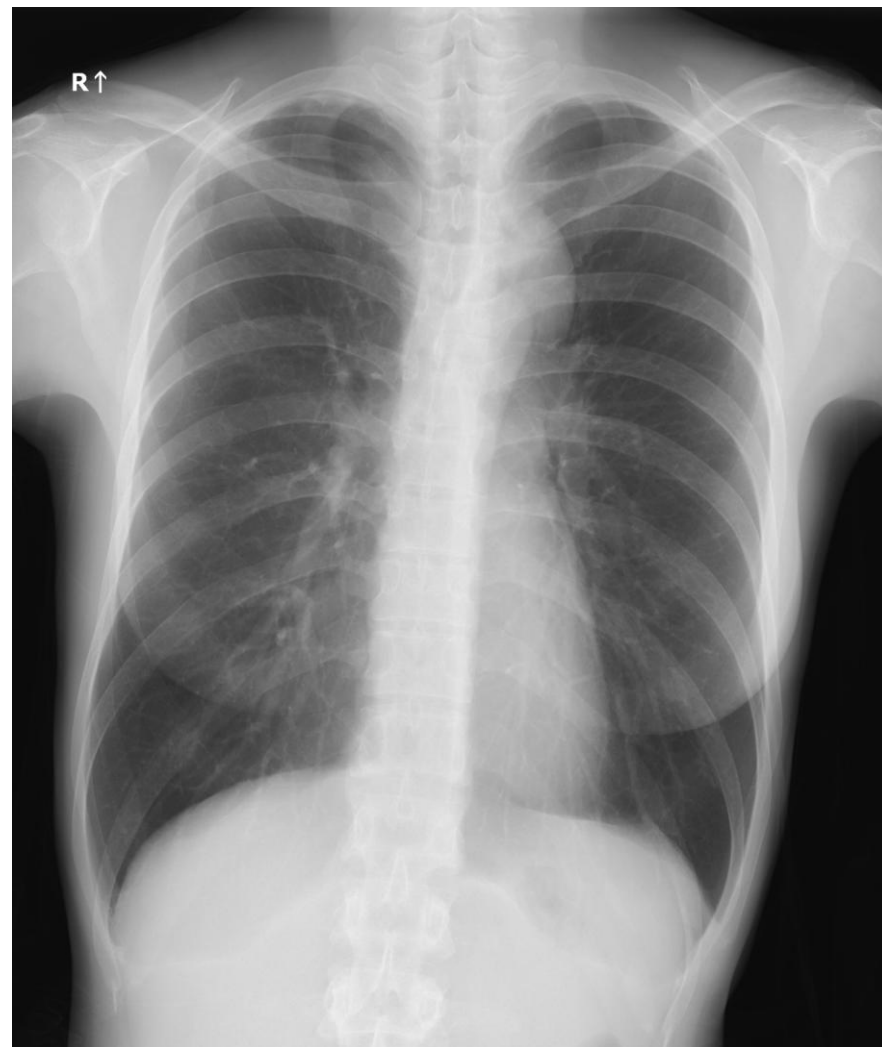


1. 胸部

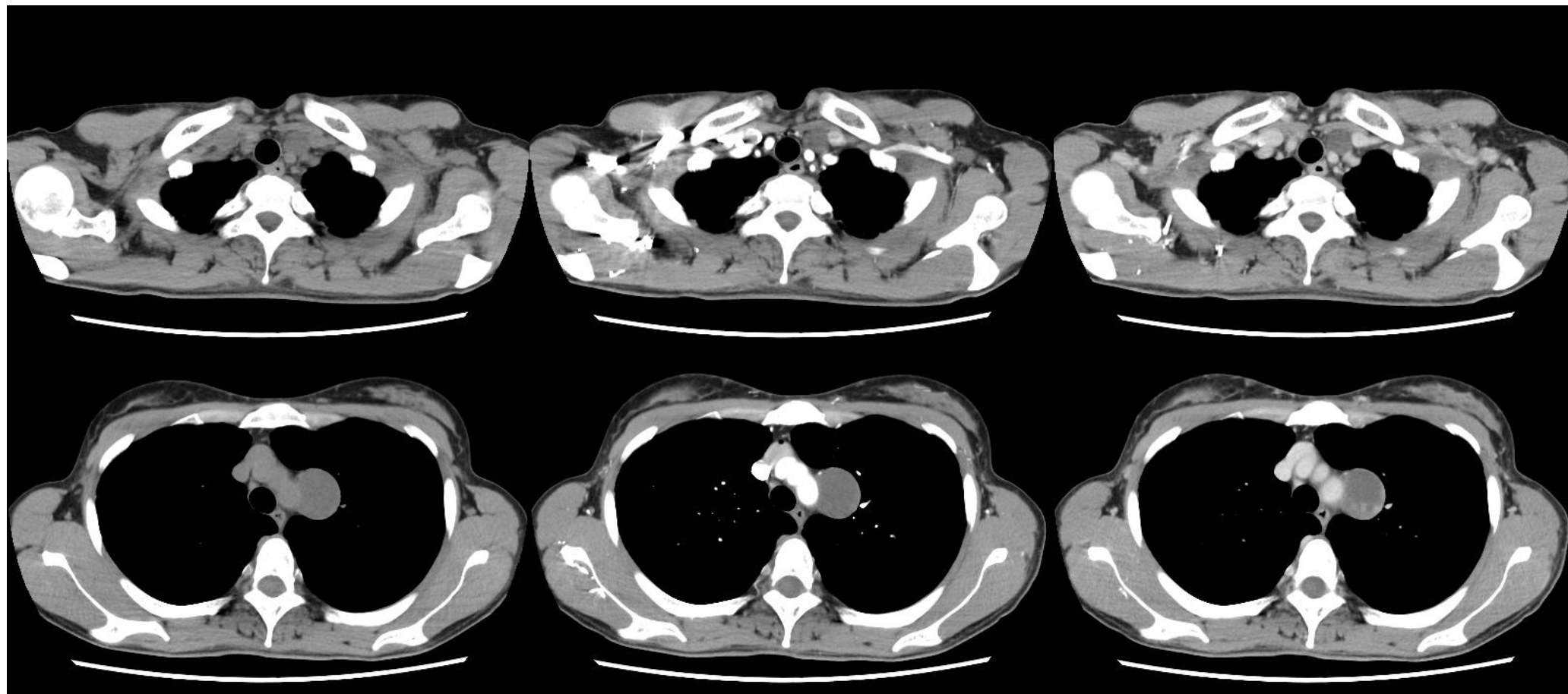
出題概要

主訴	検診異常
現病歴	検診にて縦隔腫瘍が疑われたため紹介受診
既往歴	特記事項なし
その他	40歳代 女性

胸部単純写真



CT

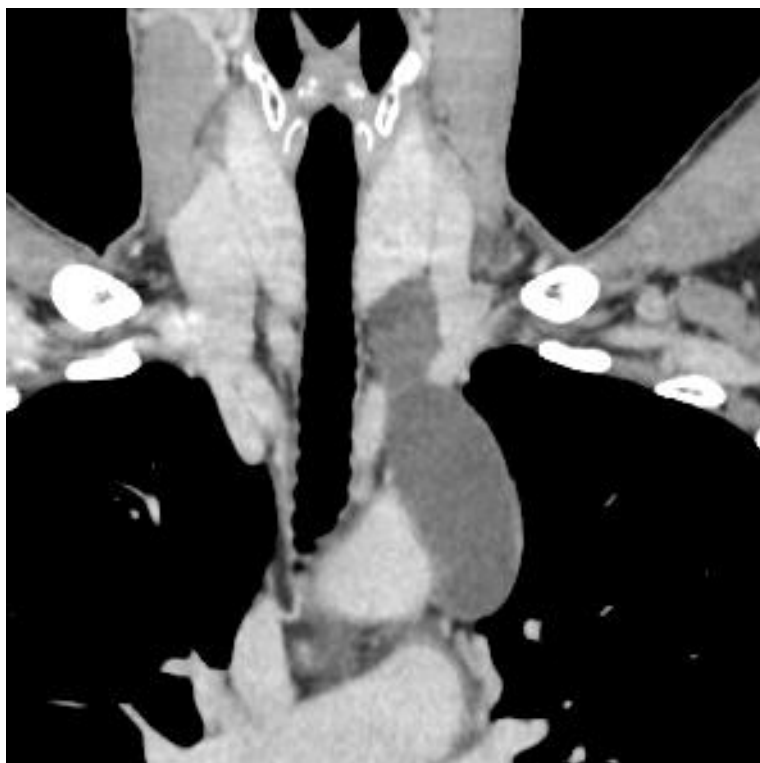

単純

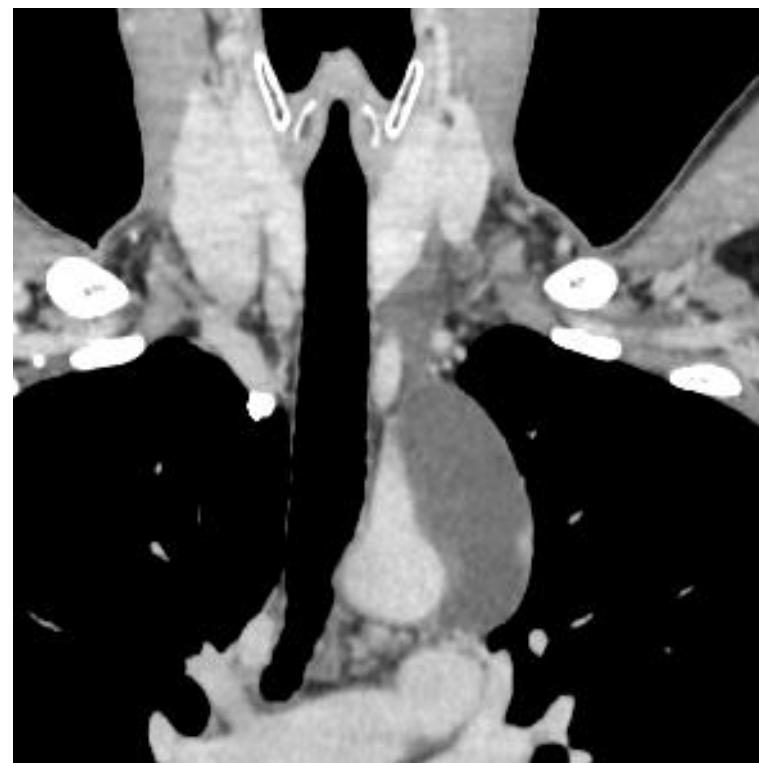
動脈相

平衡相

CT

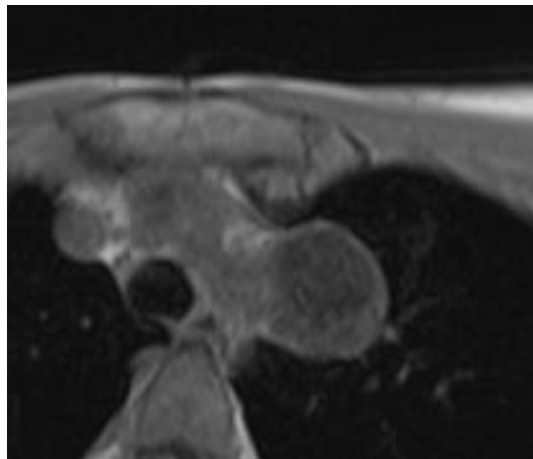


平衡相
(冠状断)

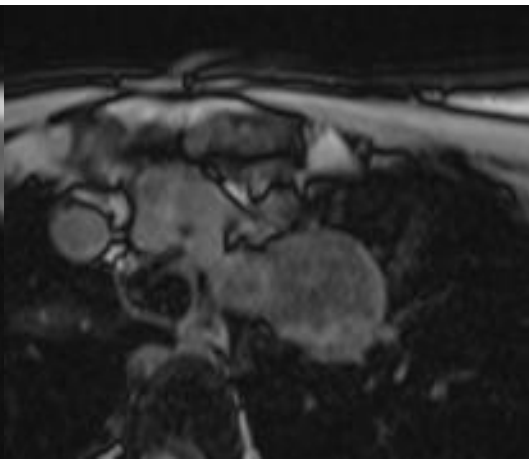


平衡相
(冠状断)

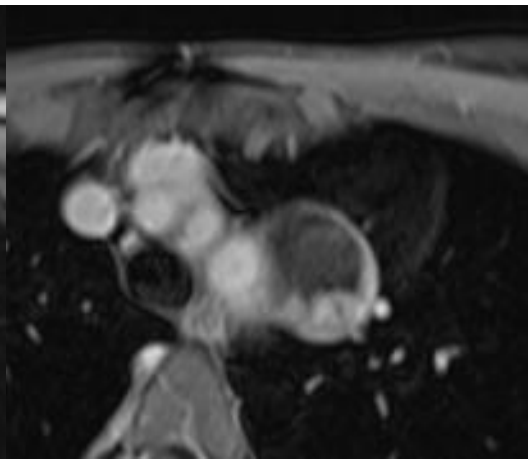
MRI



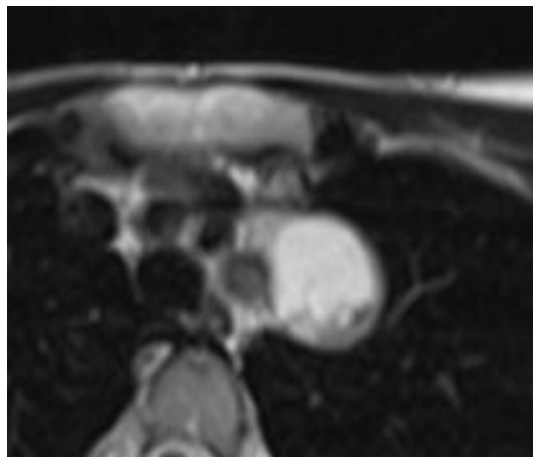
T1強調像
(in phase)



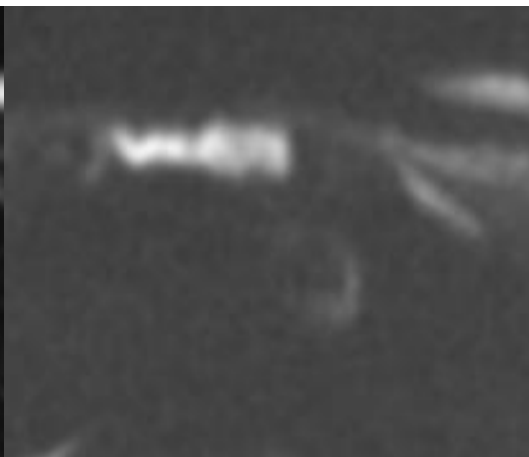
T1強調像
(opposed phase)



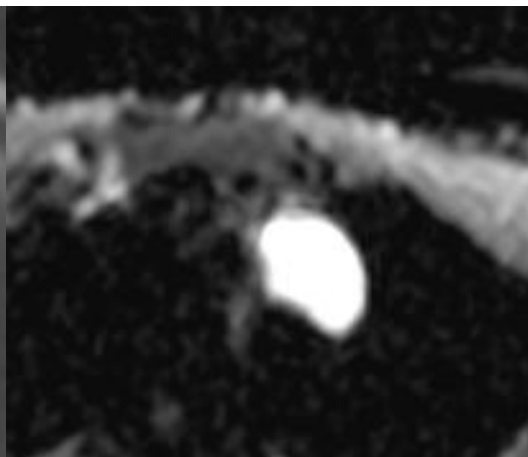
造影脂肪抑制T1強調像



T2強調像



拡散強調像



ADC map